

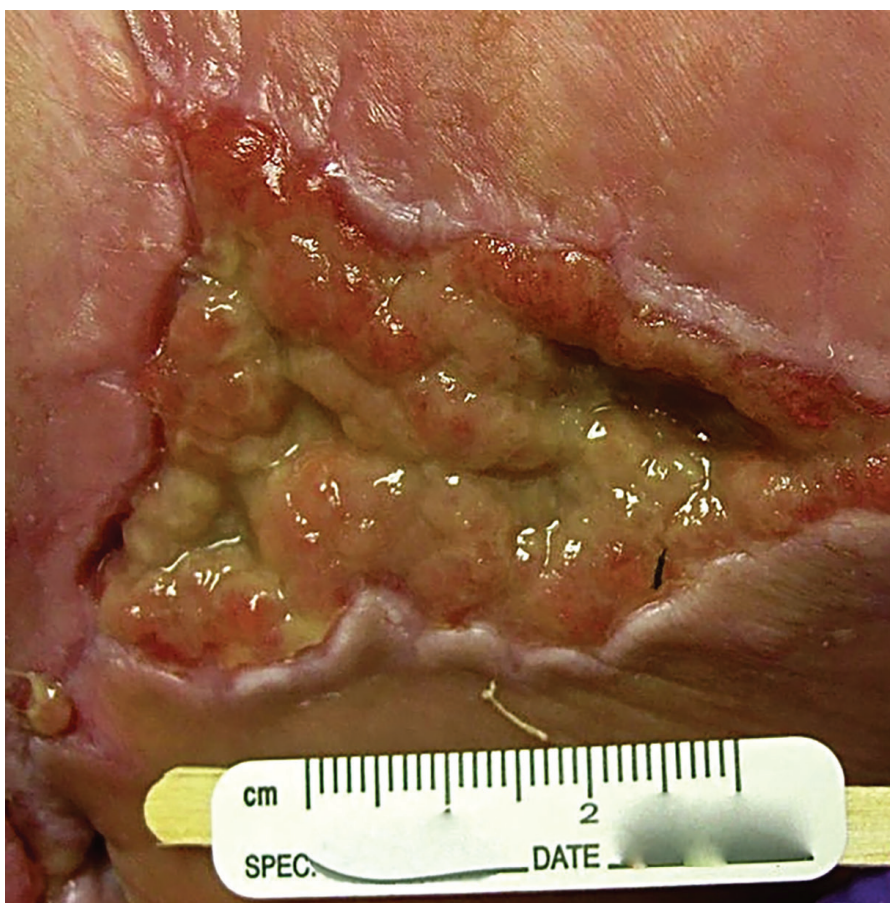

PATIENT HISTORY

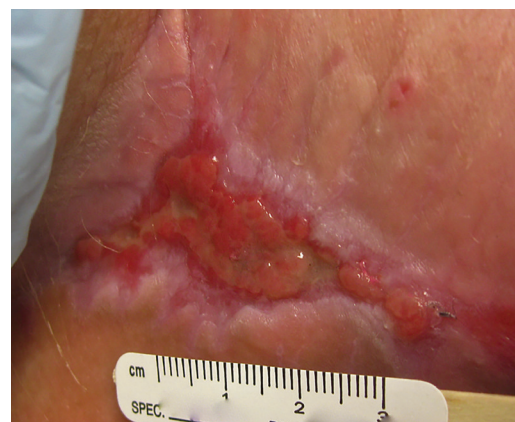A 65-year-old male underwent bilateral thigh lifts following extreme weight loss. The surgical sites in both groins and the perineum dehiscd following the procedure and developed purulent drainage. He presented to the clinic on 8/2/14. Cultures

were positive for MRSA. Past medical history was positive for prostate cancer and morbid obesity. The wounds were cleansed and irrigated with Puracyn[®] Plus Professional Formula Wound Irrigation Solution. Necrotic tissue and slough was sharply debrided from

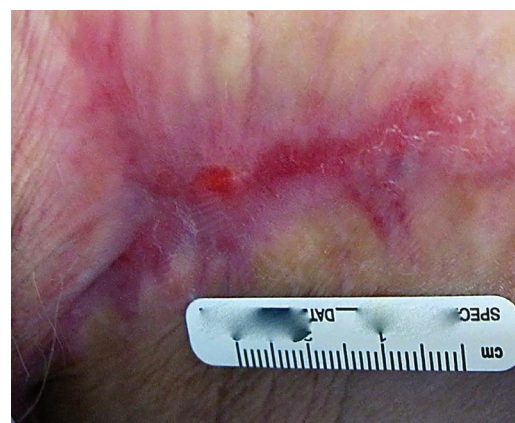
the wound bed. The wounds were dressed with sterile gauze moistened with Puracyn Plus. The patient was seen in the wound clinic twice per week for the wound care procedure as stated above. The patient was discharged on 9/16/14.



8/2/14 (WEEK 1)



8/16/14 (WEEK 2)



9/16/14 (WEEK 6)